


Copyright © 2016 by Academic Publishing House *Researcher*

Published in the Russian Federation
European Journal of Medicine
Has been issued since 2013.
ISSN: 2308-6513
E-ISSN: 2310-3434
Vol. 12, Is. 2, pp. 50-53, 2016

DOI: 10.13187/ejm.2016.12.50
www.ejournal5.com



UDC 61

Acute Kidney Injury, Multiple Myeloma and Heparin Like Syndrome

E. Dusseux ^a, V. Richez ^b, A. Appert-Flory ^c, F. Fischer ^c, M. Dodoi ^d, L. A. Vido ^a, Legros ^b, O. Moranne ^{e,*}

^aNephrology-Dialysis-Transplantation department; Nice University hospital, France

^bHematology department, Hôpital Archet 1, Nice, France

^cHematology laboratory - haemostasis; Nice University hospital, France

^dNephrology department; Cannes hospital, France

^eNephrology department; Nimes university hospital, France

Abstract

Heparin like Syndrome is an entity discovered in 1980s. Although uncommon in clinical practice, this syndrome can lead to death in many cases because of severe bleeding. We report the fourth clinical case of a heparin like Syndrome associated to multiple Myeloma and acute kidney injury with a favourable outcome. We describe the evolution of clinical bleeding as activated partial thromboplastin time (APTT) and CD138 (transmembrane heparin sulphate on tumor cells surface) dosage over time.

Keywords: multiple myeloma, partial thromboplastin time, syndrome heparin like, AKI.

1. Case report

We report the case of a 65-year-old Caucasian man. The patient's past medical history was remarkable for cardiovascular risk factor such as diabetes, hypertension, tobacco and dyslipidemia responsible for coronaropathy. He was referred in May 1996, for a chronic myeloid leukemia in chronic phase. Sokal and Hasford scores lead to low risk. He was initially treated with hydroxyurea. In July 2001, he was enrolled in the YNKO1 trial and received interferon and orally aracytine until march 2002 when treatment was switched to imatinib. Major molecular response was obtained in 2003.

In July 2012, he was hospitalized in the department of Nephrology for a severe acute kidney failure with anuria, dyspnea and bone lumbar painful evolving from one month. At the admission, the creatinine level was 1 553 µmol/l (166 µmol/l on June). Anaemia (5.9 g/L) was isolated. Total calcemia was elevated at 3.09 mmol/l. The urinary sediment revealed hematuria and leukocyturia. The ratio proteinuria/creatinuria was 2.12 g/g with tubular profile (24.1 % albumin). The partial thromboplastin time (APTT) was prolonged over 150 seconds and anti Xa activity measured at 0.56 UI/ml without heparin treatment. The serum level of free light chains Lambda was 30 100 mg/l. A Multiple Myeloma (MM) IgG Lambda Salmon and Durie stage IIIB and International Staging System stage III complicated of acute kidney failure (AKIN 3) due to a probably light chain cast nephropathy associated with haemostasis disorder was diagnosed.

* Corresponding author

E-mail addresses: olivier.moranne@chu-nimes.fr (O. Moranne)

Ultrasonography showed a bilateral enlargement (>12 cms length). A labial salivary gland biopsy was negative for diagnosis of amyloidosis. The kidney biopsy was rejected because of abnormality of coagulation with a prolonged activated partial thromboplastin time (APTT) and previous antiaggregant treatment.

Evolution was complicated by clinical hemorrhagic syndrome with severe bleeding after salivary gland biopsy and insertion of temporary haemodialysis catheter in femoral site that led to eleven red blood cell transfusion in eighteen days.

The first step was to investigate the APTT prolongation. Mixing between patient plasma and normal plasma showed no correction. Factors VIII, IX, XI, XII measurements were normal. The research of anti-phospholipid or antibodies anti-factor was negative. We concluded that the presence of a heparin like substance was responsible of the APTT and Thrombin time (TT) prolongation. The main hypothesis was a heparin like Syndrome (HLS).

Secondly, exploration of APTT in vitro showed no effect of heparinase (enzyme cleaving heparin and inhibiting its effects) (data not shown) and an effect of protamin sulfate only at high doses (Table 1).

The patient was treated therapy with MPV consisting in melphalan (Alkeran^o) (9 mg/m² D8 at D11) and prednisone (60 mg/m²) on day 6 and once a week (D13 and D20), either in association with bortezomib (Velcade^o) (1,3 mg/m²) (D7, D10, D14, D17) (Figure 1).

The normalisation of APTT was obtained at the 9th days of treatment (D15 after admission) and after the first plasmatic exchanges (Figure 1). In multiple myeloma, Syndecan-1 (CD138) has been identified as a transmembrane heparin sulphate on tumor cells surface localised in the bone marrow. We observed in the patient's plasma the decrease of cell tumor burden (marked by Syndecan-1 or CD138) correlated with the normalization of APTT (Figure 1). After 4 cycles, given a rapid decrease of M-protein component, free light chains and an improvement of overall condition and kidney clearance. A high-dose therapy with melphalan (Alkeran^o) with autologous stem cell transplantation was planned in May 2013. The dialysis treatment has been stopped in November 2012 (5 months after starting hemodialysis).

One year after MM diagnosis, the patient had a good evolution with chronic kidney disease stage 3B (CKD-EPI 41 ml/min/1.73m²).

2. Discussion

Patients with MM have an increased thrombotic risk (Auwerda et al. 2007) but there are few data concerning bleeding complications (Auwerda et al. 2007).

Bleeding complications have been the results of some abnormalities like a clinical hyperviscosity syndrome (Kwaan, Bongu, 1999), acquired Von Willebrand disease (Huang, Saidi, 2004) or hemophilia due to myeloma (Loftus, Arnold, 1994).

Moreover, another entity has been discovered due to disorder of physiologic heparinoid substance synthesis by the liver (Bienkowski, Conrad, 1984). The main role is to maintain homeostasis (Bourin, Lindahl, 1993).

In multiple myeloma, Syndecan-1 (CD138) has been identified like a transmembrane heparin sulphate on tumor cells surface localised in the bone marrow. Studies identified two functions otherwise of this CD 138: inhibitor activity on cells growth (Kato et al., 1998), (Yang et al., 2002) (ectodomain) and also biologically active heparin sulphate chains (Kato et al., 1998) (after proteolysis of the extracellular domain). High level of Syndecan 1 is an indicator of poor prognosis (Yang et al., 2002) stimulating tumor growth and dissemination.

There are only three cases reports of Heparin like syndrome in MM (Khoory et al., 1980), (Torjemane et al., 2007) complicated by a poor prognosis with death (Palmer et al., 1984), (Rodgers, Corash, 1985) because of severe bleeding. Moreover, a heparin like syndrome was described in others clinical situations like sepsis, hepatitis disorders (Llamas et al., 2000) (Senzolo et al., 2009) and breast tumour (Rodgers, Corash, 1985).

The treatment of heparin like syndrome is not well established but the treatment of the cause (hemopathy, sepsis, hepatitis) seems to be the main objective. The authors couldn't conclude on effective therapies due to few cases described and many early deaths among them.

In our case report, we think that the main treatment leading to APTT normalization was the specific myeloma treatment because of correlation between the decrease of CD138/Syndecan-1 and

APTT correction after chemotherapy (Figure 1). We think it could be discussed whether plasma exchange could help reduce the pathogenic immunoglobulin but not reduce heparinoid substances.

Table 1. Neutralization assay in vitro by protamin sulfate

	patient + 0 U/ml protamine	patient + 10 U/ml protamine	patient + 50 U/ml protamine	patient + 100 U/ml protamine	patient + 200 U/ml protamine
TT s	119,7	50,5	24,5	12,6	
AXA UI/ml	0,35	0,25	0,4	0,36	0

TT: Thrombin time; AXA: anti-factor X a activity

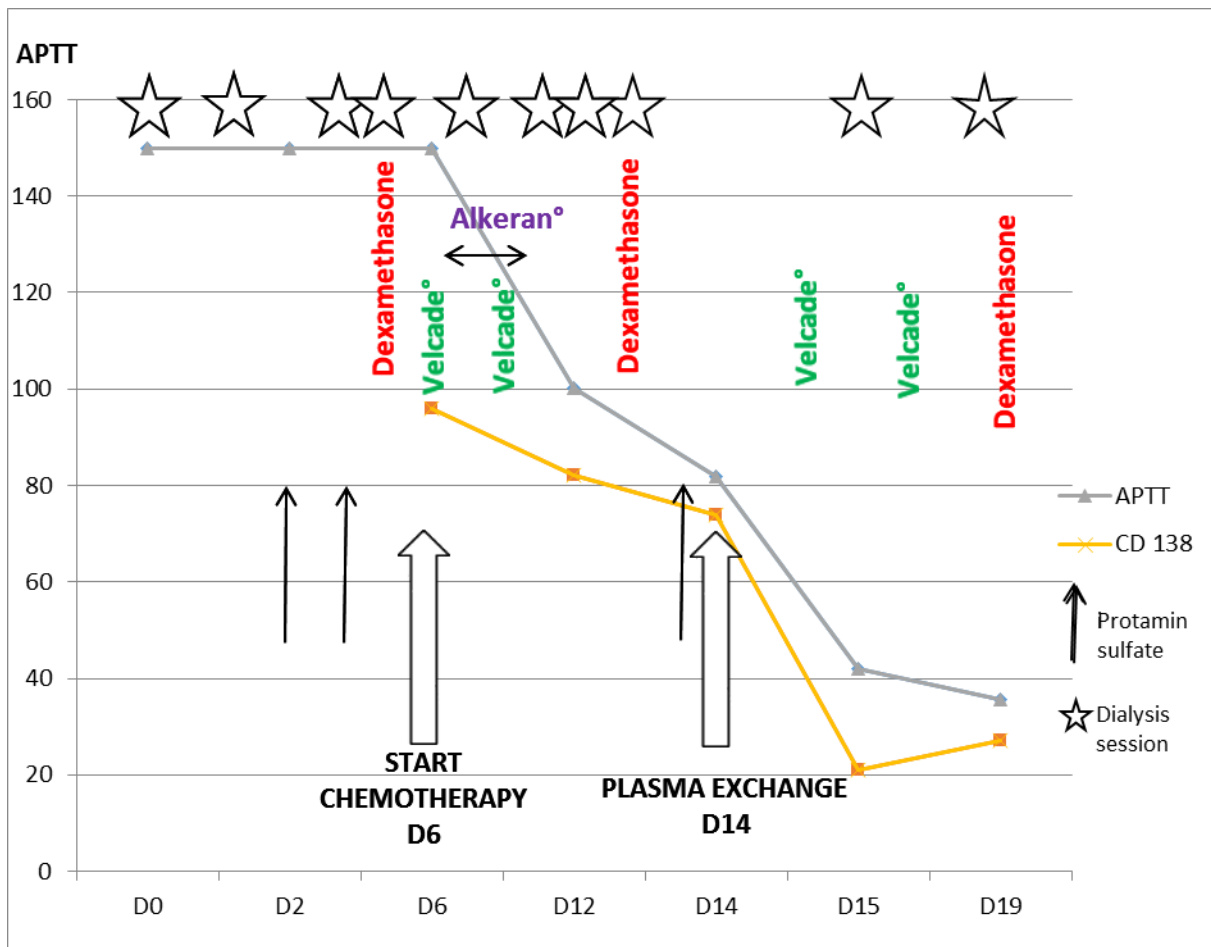


Fig. 1. APTT and CD138 evolution over the time and treatment (Do: admission day)

3. Conclusion

We report the fourth case of heparin like syndrome with hemorrhagic syndrome and acute kidney failure secondary to multiple myeloma IgG with good evolution.

In this case, start quickly chemotherapy treatment permit to control severe hemorrhagic complications.

References

- [Auwerda et al. 2007](#) - *Auwerda JJA, Sonneveld P, de Maat MPM, Leebeek FWG* (2007). Prothrombotic coagulation abnormalities in patients with newly diagnosed multiple myeloma. *Haematologica*. févr 2007; 92(2), pp. 279-280.
- [Bienkowski, Conrad, 1984](#) - *Bienkowski M.J., Conrad H.E.* (1984). Kinetics of proteoheparan sulfate synthesis, secretion, endocytosis, and catabolism by a hepatocyte cell line. *J Biol Chem*. 11 oct 1984; 259(21), pp. 12989-96.
- [Bourin, Lindahl, 1993](#) - *Bourin M.C., Lindahl U.* (1993). Glycosaminoglycans and the regulation of blood coagulation. *Biochem J*. 15 janv 1993; 289(Pt 2), pp. 313-330.
- [Huang, Saidi, 2004](#) - *Huang Y-W., Saidi P.* (2004). Acquired von Willebrand disease in a patient with monoclonal gammopathy of undetermined significance. *Am J Med Sci*. févr 2004; 327(2), pp. 98-101.
- [Kato et al., 1998](#) - *Kato M., Wang H., Kainulainen V., Fitzgerald M.L., Ledbetter S., Ornitz D.M. et al.* (1998). Physiological degradation converts the soluble syndecan-1 ectodomain from an inhibitor to a potent activator of FGF-2. *Nat Med*. juin 1998; 4(6), pp. 691-697.
- [Khoory et al., 1980](#) - *Khoory M.S., Nesheim M.E., Bowie E.J., Mann K.G.* (1980). Circulating heparan sulfate proteoglycan anticoagulant from a patient with a plasma cell disorder. *J Clin Invest*. mars 1980; 65(3), pp. 666-674.
- [Kwaan, Bongu, 1999](#) - *Kwaan H.C., Bongu A.* (1999). The hyperviscosity syndromes. *Semin Thromb Hemost*. 25(2), pp. 199-208.
- [Llamas et al., 2000](#) - *Llamas P., Prieto E., Román A., Espinoza J., Soto C., Tomás J.F.* (2000). Abnormal bleeding in a patient with chronic lymphocytic leukemia and acute hepatitis due to a circulating heparin-like anticoagulant. *Haematologica*. juill 2000; 85(7), pp. 777-778.
- [Loftus, Arnold, 1994](#) - *Loftus L.S., Arnold W.N.* (1994). Acquired hemophilia in a patient with myeloma. *West J Med*. févr 1994; 160(2), pp. 173-176.
- [Palmer et al., 1984](#) - *Palmer R.N., Rick M.E., Rick P.D., Zeller J.A., Gralnick H.R.* (1984). Circulating heparan sulfate anticoagulant in a patient with a fatal bleeding disorder. *N Engl J Med*. 28 juin 1984;310(26), pp. 1696-1699.
- [Rodgers, Corash, 1985](#) - *Rodgers G.M., Corash L.* (1985). Acquired heparinlike anticoagulant in a patient with metastatic breast carcinoma. *West J Med*. nov 1985;143(5), pp. 672-675.
- [Senzolo et al., 2009](#) - *Senzolo M., Agarwal S., Zappoli P., Vibhakorn S., Mallett S., Burroughs A.K.* (2009). Heparin-like effect contributes to the coagulopathy in patients with acute liver failure undergoing liver transplantation. *Liver Int*. mai 2009; 29(5), pp. 754-759.
- [Torjemane et al., 2007](#) - *Torjemane L., Guermazi S., Ladeb S., Ben Romdhane N., Lakhal A., Abdelkefi A., et al.* (2007). Heparin-like anticoagulant associated with multiple myeloma and neutralized with protamine sulfate. *Blood Coagul Fibrinolysis Int J Haemost Thromb*. avr 2007; 18(3), pp. 279-281.
- [Yang et al., 2002](#) - *Yang Y., Yaccoby S., Liu W., Langford J.K., Pumphrey C.Y., Theus A. et al.* (2002). Soluble syndecan-1 promotes growth of myeloma tumors in vivo. *Blood*. 15 juill 2002; 100(2), pp. 610-617.