

Copyright © 2021 by Academic Publishing House Researcher s.r.o.



Published in the Slovak Republic
European Journal of Medicine
Has been issued since 2013.
E-ISSN: 2310-3434
2021. 9(1): 9-19

DOI: 10.13187/ejm.2021.1.9
www.ejournal5.com



Radiofrequency Microneedling for the Treatment of Acne Scar in Iraqi Patients

Narjis Sattar Jabbar ^a, Wesam Ahmed Jawad ^a, Mohammed Maseer Zyara ^a

^aAl-Kindy Teaching Hospital, Baghdad, Iraq

Abstract

The study was done to evaluate the role of radiofrequency micro needling as a treatment modality in treating acne scars. This study is a prospective follow up study carried out in a private clinic through the period from 1st of August, 2017 to 31st of July, 2018 on convenient sample of 60 patients with acne scars.

The acne scars were classified and treatment evaluated according to qualitative and quantitative Goodman and Baron's Acne Scarring System. the radiofrequency micro needling treatment outcome of acne scar patients was distributed as followings; minimal (20 %), moderate (31.7 %), good (38.3 %) and very good (10 %) and patients' satisfaction regarding radiofrequency micro needling treatment of acne scar was distributed as followings; 13.3 % no change, 10 % slight improvement 23.3 % moderate improvement, 30 % significant improvement and 23.3 % excellent improvement. The recorded side effects were minor; erythema (20 %), pain (6.7 %), hyperpigmentation (5 %) and edema (3.3 %).

In conclusion: The radiofrequency micro needling treatment modality of acne scar is effective and safe.

Keywords: Acne, scar, micro needling, radiofrequency, Iraqi patients.

1. Introduction

Acne is a common condition with prevalence as high as 80 % among adolescents. All body areas with high concentrations of pilosebaceous glands may be involved, but the commonest affected areas include the face, back and chest. Acne lesions can result in permanent scarring with a marked impact on quality of life. Genetic factors, disease severity and delay in treatment are the main factors influencing scar formation. The prevalence and severity of acne scarring in the population is largely unknown (Gozali, Zhou, 2015).

Scar severity is another important factor in the management of scars. It is used as a tool of identifying a suitable treatment to evaluate outcomes (Goodman, Baron, 2006). Several different modalities have been devised. Such assessments can be objective or subjective examples of such grading scales include the Vancouver Scar Scale (VSS), Goodman and Baron Qualitative and Qualitative grading scales, Patient and Observer Scar Assessment Scale (POSAS), Visual Analog Scale (VAS) and the Patient Satisfaction Score (PSS) (Fearmonti et al., 2010). Furthermore, different treatments was used of acne scar such as Pulsed dye laser (PDL). PDL is the gold-standard for treating scar-associated erythema (Iyer et al., 2005).

Traditional ablative lasers considered the gold standard in acne scarring treatment (Brightman et al., 2009), ablative fractional lasers (Ong, Bashir, 2012), traditional non-ablative lasers, non-ablative fractionated lasers (Maluki, Mohammad, 2012), non-ablative radiofrequency (RF) treatments can be used as a monotherapy or adjuvant therapy with fractional lasers. Radiofrequency delivers a current through the dermis that stimulates dermal remodeling,

producing new collagen and softening scar defects (Simmons et al., 2014). New developments have allowed for more precision in the delivery of RF energy to deeper tissues, with decreased injury to the overlying epidermis. Bipolar RF allows for delivery of a more focused current to the dermis.

Microneedle bipolar RF and fractional bipolar RF treatments offer the best results for acne scarring, particularly icepick and boxcar scars (Min et al., 2015), as well as, radiofrequency and microneedling were subsequently combined in an attempt to enhance the results that could be achieved with either one alone.

The combination technology creates fractional radiofrequency coagulation of dermal collagen and results in immediate collagen contraction. It also stimulates a natural healing response which leads to the replacement of damaged connective tissue with new healthier skin (Garg, Baveja, 2014).

The microneedling Fractional Radiofrequency (MFR) device, which delivers heating in a fractional manner, was introduced for the use in skin treatments including skin rejuvenation, acne scar, axillary hyperhidrosis, and striae alba.

The MFR device delivers uniform heat at a controlled depth to the dermal-hypodermal layers where the sweat glands and hair follicles are present, resulting in thermolysis of the sweat glands and subsequent necrosis (Fatemi et al., 2016). The study was aimed to evaluate the role of radiofrequency microneedling as a treatment modality in treating acne scars.

Patients and methods

Study design, settings and duration

This study is a prospective follow up study carried out in a private clinic (Dr. Wesam Al-Saraf Clinic) through the period from 1st of August, 2017 to 31st of July, 2018.

Population

All patients presented with acne scars to the clinic. With inclusion criteria included Adults (age \geq 20 years) and Acne scars.

Exclusion criteria: it is included the following: previous treatment of acne scars, Laser therapy during treatment or during follow up, Photosensitivity, Pregnancy and lactation, Hypertrophic or Keloid scarring, Patients On isotretinoin treatment or Anticoagulants history, Active herpes infection and Refused to participate.

Sampling

A convenient sample of 60 patients with acne scars presented to private clinic was enrolled in the study after filling the inclusion and exclusion criteria.

Data Collection

The data was collected through direct interview with acne scar patients and fulfilling a prepared questionnaire. The diagnosis of acne scars was confirmed by Dermatologist in the clinic. The questionnaire was prepared by the supervisor and researcher.

The questionnaire included the followings: Demographic characteristics: Age and gender, skin type of patients with acne scars, acne scar types, age at acne and acne scars development, treatment outcome assessment by physicians and Patients' satisfaction in treatment outcomes. After full history and examination of patients by the researcher, the acne scars were carefully examined and classified according to qualitative and quantitative Goodman and Baron's Acne Scarring System (Goodman, Baron, 2006; Al-Hammamy et al., 2015). The acne scars selected in this study were mild to severe acne scars according to grading of Goodman. The treatment plan of acne scar by microneedling and radiofrequency was organized in four sessions lasting for 6 months with a schedule of 1st visit, 2nd month, 4th month and 6th month.

Microneedling and radiofrequency treatment

The equipment used was (Micro-needle and Fractional Radiofrequency tb-88) and the researcher was trained on using this equipment by Dermatologist in the clinic. Before application of treatment, the face was cleansed using non-abrasive detergent and gauzes soaked in 70 % isopropyl alcohol. Additionally, the topical anesthetic cream (EMLA) was used under occlusive dressing for 1 hour duration and then removed. The power and intensity of microneedling and radiofrequency applied is dependent on acne scar grade and depth. The device had dual handpieces and two head tips of different sizes, 25 and 49 pins. The intensity was 7 with active pulse 210 ms, in depth of 1.5 mm at 0.5 sec. interval. The forced air cooling is essential to maintain comfort of patients.

The treatment was administered in four sessions during a period of 6 months in a schedule of 1st visit, 2nd month, 4th month and 6th month.

Follow up and assessment

The acne scars patients were followed up during treatment four sessions and the final assessment was done after completing 6 months or four session's treatment with microneedle and radiofrequency.

Treatment outcomes were assessed by standardized digital photography (SONY-DSC-W300; 13.6 mega pixels) by the patient himself and by the researcher and other Dermatologist. The dermatologists' evaluation was depending on quantitative Goodman and Baron's Acne Scarring System outcome assessment (Goodman, Baron, 2006; Al-Hammamy et al., 2015). This assessment was categorized into four groups as shown in Table 1.

Table 1. Assessment of improvement of acne scar using Goodman and Baron's Acne Scarring System (Goodman, Baron, 2006; Al-Hammamy et al., 2015)

Grades	Improvement status
0-5	Minimal reduction in GSGS score
5-10	Moderate reduction in GSGS score
10-15	Good reduction in GSGS score
>15	Very good reduction in GSGS score

The self-assessment level of improvement of the patients was evaluated using the following five-point scale:

- 0=no change;
- 1=slight improvement (0-25 %);
- 2=moderate improvement (26-50 %);
- 3=significant improvement (51-75 %);
- 4=excellent improvement (>75 %).

The two assessors were blinded to the order of the photographs. The evaluators were asked to perform two actions. First, to identify the photograph that showed better scar appearance. Second, to rate the difference in the severity of the acne scars using the above mentioned scale.

Statistical analysis

All patients' data entered using computerized statistical software; Statistical Package for Social Sciences (SPSS) version 20 was used. Descriptive statistics presented as (mean \pm standard deviation) and frequencies as percentages. Multiple contingency tables conducted and appropriate statistical tests performed, Fishers exact test was used for categorical variables. In all statistical analysis, level of significance (p value) set at ≤ 0.05 and the result presented as tables and/or graphs. Statistical analysis of the study was done by the community medicine specialist.

2. Results

Age of patients

The present study included 60 patients with acne scars; with mean age of 25.9 \pm 3.9 years, 50 % of them were in age group 20-25 years, 36.7% of them were in age group 26-30 years and 13 % of them were in age group 31-35 years. All these findings were shown in Table 2.

Table 2. Age of acne scar patients

Variable	No.	%
Age mean±SD (25.9±3.9 years)		
20-25 years	30	50.0
26-30 years	22	36.7
31-35 years	8	13.3
Total	60	100.0

Gender of patients

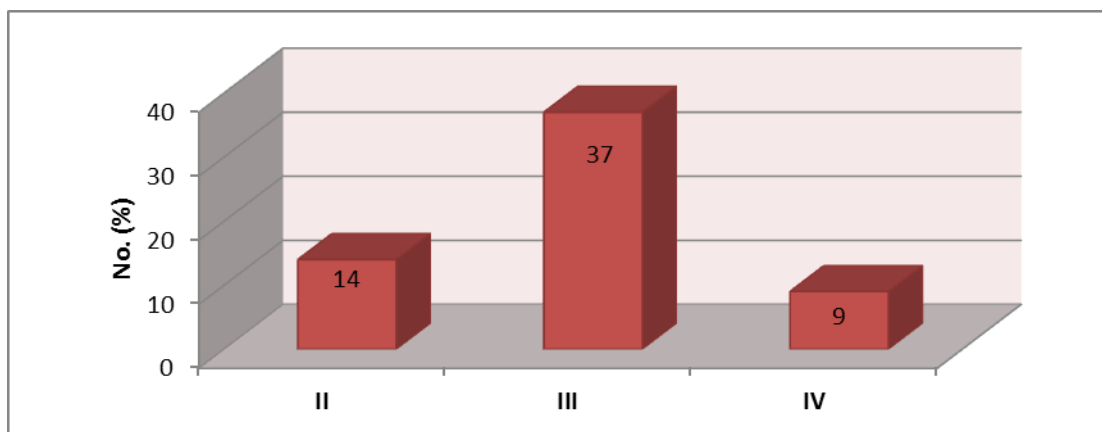
More than two thirds (80 %) of acne scar patients were females and 20% of acne scar patients were males with female to male ratio as 4:1. All these findings were shown in [Table 3](#).

Table 3. Gender distribution of acne scar patients

Variable	No.	%
Gender		
Male	12	20.0
Female	48	80.0
Total	60	100.0

Skin types

The skin types of acne scar patients were distributed as following; 23.3 % type II, 61.7 % type III and 15 % type IV. All these findings were shown in [Figure 1](#).

**Fig. 1.** Skin types**Acne scar types**

The acne scar types for studied patients were distributed as followings; significant rolling (26.7 %), deep boxcar (20 %), shallow boxcar (35 %), and icepick scar (18.3 %). All these findings were shown in [Figure 2](#).

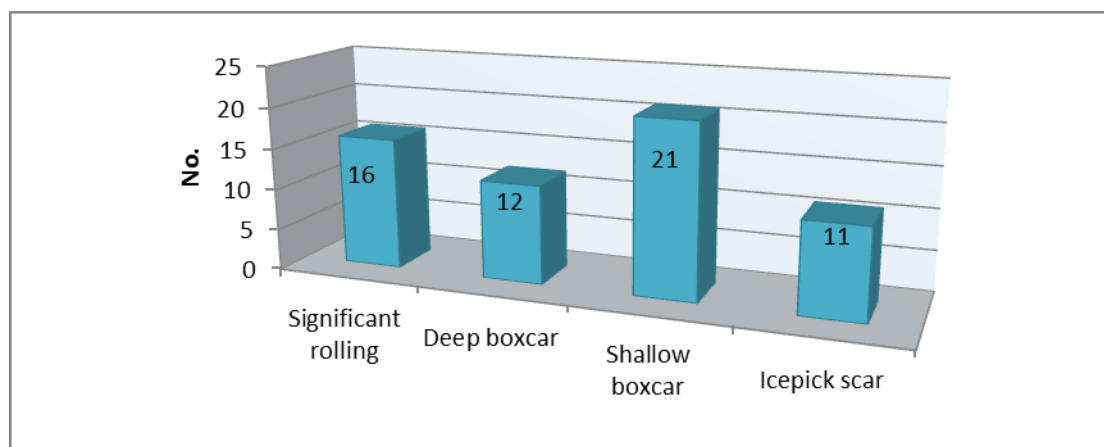


Fig. 2. Types of acne scars

Age at onset

Mean age of patients at onset of acne was 16 ± 1.5 years; 70 % of them had acne at age group 14-16 years and 30 % of them had acne at age group 17-19 years. Mean age of patients at onset of acne scar was 19.6 ± 1.5 years; 46.7 % of them had acne at age group 17-19 years and 53.3 % of them had acne at age of 20 years and more. All these findings were shown in [Table 4](#).

Table 4. Age at onset of acne and acne scar development

Variable	No.	%
Age at acne onset mean\pmSD (16\pm1.5 years)		
14-16 years	42	70.0
17-19 years	18	30.0
Total	60	100.0
Age at acne scar onset mean\pmSD (19.6\pm1.5 years)		
17-19 years	28	46.7
≥ 20 years	32	53.3
Total	60	100.0

Treatment outcome

According Goodman and Baron's Acne Scarring System outcome assessment, the Micro-needling Radiofrequency (MR) treatment outcome of acne scar patients was distributed as followings; minimal (20 %), moderate (31.7 %), good (38.3 %) and very good (10 %). All these findings were shown in [Table 4](#).

Table 5. MR treatment outcome of acne scar by Goodman and Baron's Acne Scarring System

Variable	No.	%
Treatment outcome		
Minimal	12	20.0
Moderate	19	31.7
Good	23	38.3

Very good	6	10.0
Total	60	100.0

Patients satisfaction

The patients' satisfaction regarding MR treatment of acne scar was distributed as followings; 13.3 % no change, 10 % slight improvement 23.3 % moderate improvement, 30 % significant improvement and 23.3 % excellent improvement. All these findings were shown in [Table 6](#).

Table 6. Patients' satisfaction toward MR treatment of acne scar

Variable	No.	%
Patients satisfaction		
No change	8	13.3
Slight improvement	6	10.0
Moderate improvement	14	23.3
Significant improvement	18	30.0
Excellent improvement	14	23.3
Total	60	100.0

Relationship between MR outcome and study variables

As shown in [Table 7](#), there was a significant association between increased age of patients with acne scar and good MR treatment outcome ($p = 0.002$).

Table 7. Distribution of patients' age according to MR treatment outcome

Age groups	Minimal		Moderate		Good		Very good		P
	No.	%	No.	%	No.	%	No.	%	
20-25 years	4	33.3	12	63.2	14	60.9	0	-	0.002* Significant
26-30 years	8	66.7	6	31.6	3	13.0	5	83.3	
31-35 years	0	-	1	5.3	6	26.1	1	16.7	

*Fishers exact test

As shown in [Table 8](#), no significant differences were observed between acne scar patients with different MR outcomes regarding patients gender ($p = 0.2$).

Table 8. Distribution of patients' gender according to MR treatment outcome

Gender	Minimal		Moderate		Good		Very good		P
	No.	%	No.	%	No.	%	No.	%	
Male	4	33.3	5	26.3	2	8.7	1	16.7	0.2* Not significant
Female	8	66.7	14	73.7	21	91.3	5	83.3	

*Fishers exact test

As shown in [Table 9](#), no significant differences were observed between acne scar patients with different MR outcomes regarding patients skin types ($p = 0.7$).

Table 9. Distribution of patients' skin types according to MR treatment outcome

Skin type	Minimal		Moderate		Good		Very good		P
	No.	%	No.	%	No.	%	No.	%	
II	2	16.7	6	31.6	5	21.7	1	16.7	0.7* Not significant
III	7	58.3	11	57.9	14	60.9	5	83.3	
IV	3	25.0	2	10.5	4	17.4	0	-	

*Fishers exact test

As shown in Figure 3, there was a significant association between significant rolling acne scar and very good MR treatment outcome (p = 0.001).

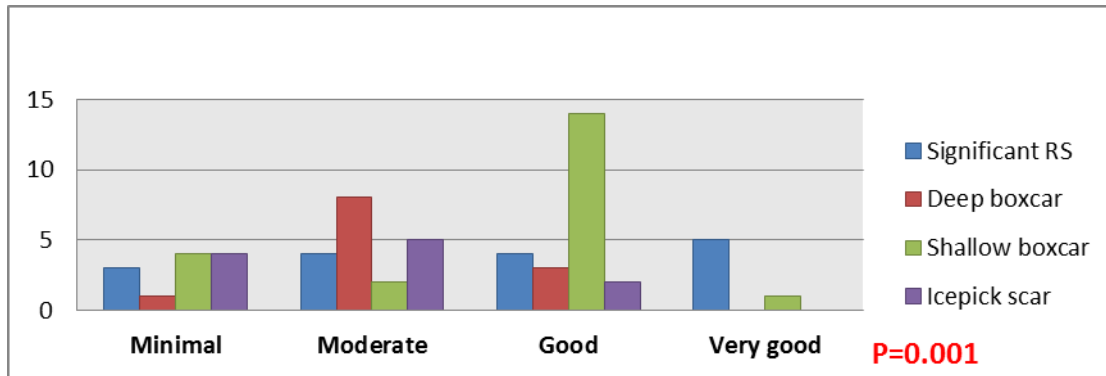


Fig. 3. Distribution of MR outcome according to acne scar types

MR post-treatment side effects

As shown in Figure 4, no side effects were observed after MR treatment of acne scars among 39 (65 %) patients, while the present side effects included erythema (20 %), pain (6.7 %), hyperpigmentation (5 %) and edema (3.3 %).

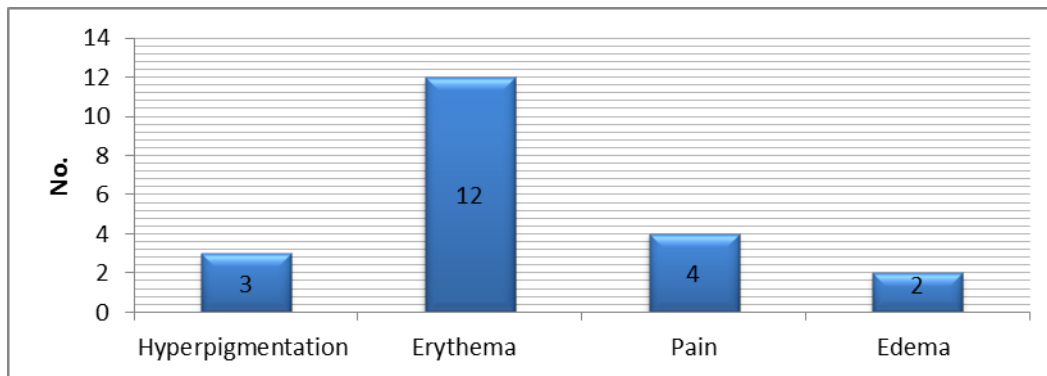


Fig. 4. Side effects of acne scar treatment by MR

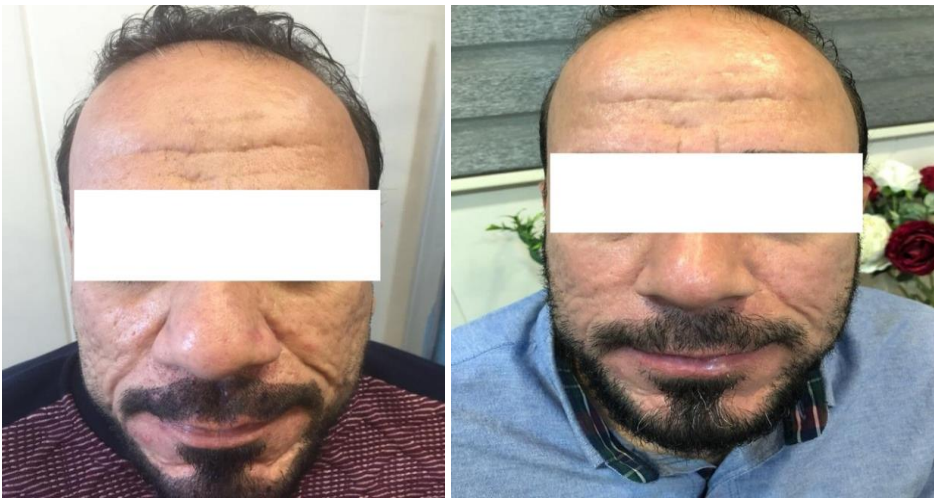

Fig. 5. Male patient with acne scar; Left pre-treatment, Right post-treatment (anterior view)

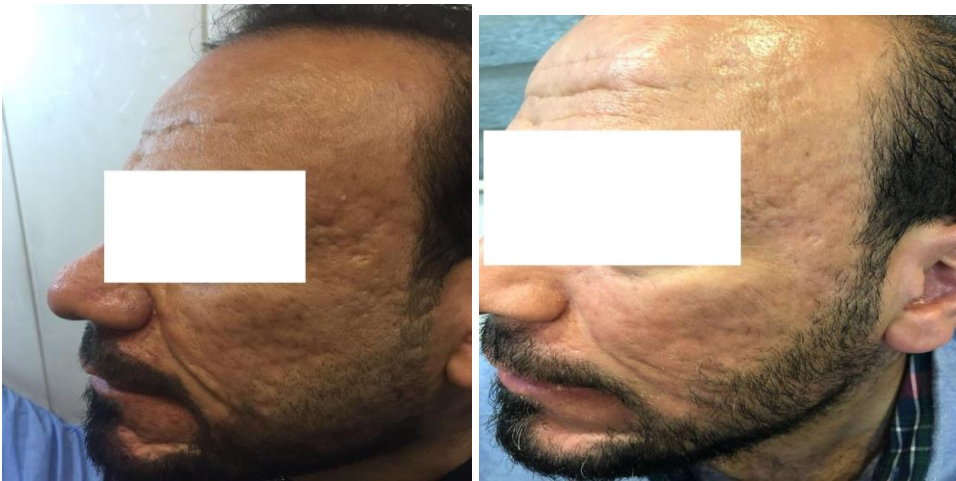

Fig. 6. Male patient with acne scar; Left pre-treatment, Right post-treatment (lateral view)

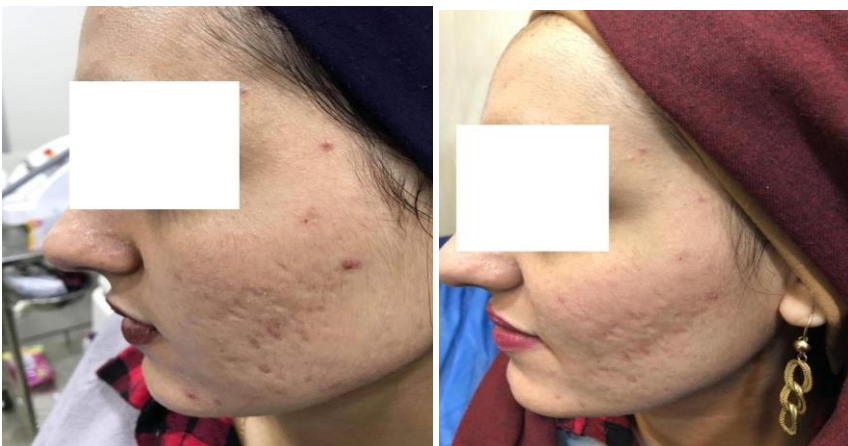

Fig. 7. Female patient with acne scar; Left pre-treatment, Right post-treatment (lateral view)

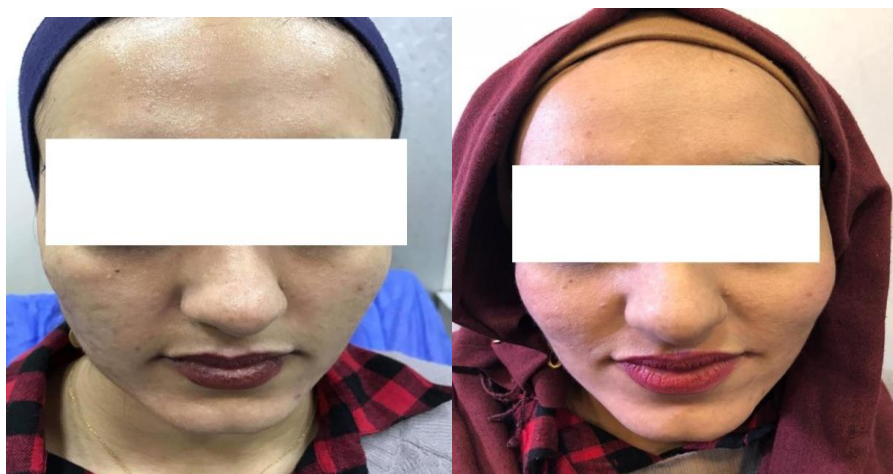

Fig. 8. Female patient with acne scar; Left pre-treatment, Right post-treatment (anterior view)

3. Discussion

The current study showed that outcome of using microneedling and radiofrequency in treating after four sessions resulted in 20 % minimal improvement, 31.7 % moderate improvement, 38.3 % good improvement and 10 % very good improvement according Goodman and Baron's Acne Scarring System outcome assessment. These outcome results are better than results of Chandrashekar et al. (2014). Study in India which evaluated the outcome of four session's microneedling fractional radiofrequency for 6 months in treatment of acne scars and ended in 29 % minimal improvement, 58 % moderate improvement, 9 % good improvement and 3 % very good improvement. In Iraq, a study conducted by Al-Hammamy et al. (2015), revealed that subcision and microneedling are safe and effective treatment procedure for acne scars with long term outcome. A study conducted in South Korea by Min et al. (2015), evaluated the microneedling and radiofrequency modality in comparison to bipolar radiofrequency in treating acne scars and showed that microneedling radiofrequency had higher efficacy and safety for treatment of acne scars. The micro-needling is the public choice in treating the facial atrophied acne scars. In a review of literatures conducted by Harris et al. (2015), in Australia, there was moderate evidence confirming the effectiveness and safety of microneedling in treating the facial acne scars. The action of microneedling is aiming to re-establishment and building up new collagen fibers, elastin and capillaries (Singh et al., 2016). Current Egypt study revealed that microneedling application for acne scar treatment causes a rising in collagen fibers after 6 sessions. Enhancing new synthesis of percutaneous collagen by microneedling refresh the skin and influence the youthful expression of skin through lowering fine lines and wrinkles, decreasing pore size, increase in suppleness and more elastic texture. Adding the radiofrequency to microneedling would create radiofrequency thermal zones without epidermal injury that lead to increase the thickness of skin dermis by new skin dermis organization, new collagen and elastin fibers (Chandrashekar et al., 2014).

Current study found that satisfaction of patients with acne scars regarding outcome of microneedling and radiofrequency in treating acne scars was significant to excellent in more than half of patients, while 13.3 % of patients had perceived no change, 10 % perceived slight improvement and 23.3 % of them perceived moderate improvement. These findings are better than results of Saeed et al. (2016), study in Iraq which evaluated the outcome of microneedling radiofrequency alone or in combination with platelets-rich plasma and found that satisfaction of patients toward outcome of microneedling radiofrequency alone was distributed as followings; 4.5 % no improvement, 27.3 % mild improvement, 27.3 % moderate improvement, 27.3 % good improvement and 4.5 % excellent improvement (Saeed et al., 2016).

In present study, the side effects were not observed in 65 % of acne scars patients treated with microneedling and radiofrequency. This finding is consistent with results of Min et al. (2015), study in South Korea and Hussain (2018). In Pakistan which documented minor side effects of post treatment of acne scars with microneedling radiofrequency. The common side effects reported in our study were erythema, pain, hyperpigmentation and edema. These findings are similar to results of Elawar and Dahan (2018), in France which evaluated the outcome of microneedling

radiofrequency in treating the acne scars and found that this treatment modality was highly effective with high patients' satisfaction and minimum side effects like erythema and pain. In Thailand, Vejjabhinanta et al. (2014), carried out a study evaluation the role of microneedling radiofrequency in treatment of acne scars and reported that main adverse effects occurred after treatment were pain, erythema, scabbing and pigmentary alterations.

Our study showed a significant association between increased age of patients with acne scar and good microneedling radiofrequency treatment outcome ($p = 0.002$). This finding coincides with results recorded by O'Daniel (2011) in USA. In China Gozali and Zhou (2015) reported that microneedling is effective in treating acne scars of aging face as it replaces the atrophied scars with neo collagen fibers specifically for elderly age women. Present study showed also a significant association between significant rolling acne scar and very good microneedling radiofrequency treatment outcome ($p = 0.001$). This finding is similar to results obtained by Kravvas and Al-Naimi (2017), who stated that boxcar acne scars are difficult to be treated while the rolling acne scars are easily treated. However, many authors clarified the effectiveness of microneedling and radiofrequency modality in treating the acne scars generally and rolling acne scars specifically (Chandrashekar et al., 2014).

4. Conclusion

The study concluded, the microneedling radiofrequency treatment modality of acne scar is effective and safe and satisfactory for patients with acne scars. microneedling radiofrequency have adverse side effects including erythema, pain, hyperpigmentation and edema. As well as, the improvement rate of acne scars treated with microneedling and radiofrequency is more likely to be affected by age of patients and type of acne scar.

Declaration of competing interest

None.

Funding

None.

References

- Al-Hammamy et al., 2015 – Al-Hammamy, H.R., Mohammad, A-AS, Al-Turfy, I.A. (2015). Subcision in the Treatment of Acne Scar in Iraqi Patients. *Journal of Cosmetics, Dermatological Sciences and Applications*. 5: 125-133.
- Brightman et al., 2009 – Brightman, L.A., Brauer, J.A., Anolik, R. (2009). Ablative and fractional ablative lasers. *Dermatol Clin*. 27: 479-489.
- Chandrashekar et al., 2014 – Chandrashekar, B.S., Sriram, R., Mysore, R., Bhaskar, S., Shetty, A. (2014). Evaluation of microneedling fractional radiofrequency device for treatment of acne scars. *J Cutan Aesthet Surg*. 7(2): 93-97.
- Elawar, Dahan, 2018 – Elawar, A., Dahan, S. (2018). Non-insulated Fractional Microneedle Radiofrequency Treatment with Smooth Motor Insertion for Reduction of Depressed Acne Scars, Pore Size, and Skin Texture Improvement: A Preliminary Study. *J Clin Aesthet Dermatol*. 11(8): 41-44.
- Fatemi et al., 2016 – Fatemi, N.F., Behfar, S., Abtahi-Naeini, B., Keyvan, S., Pourazizi, M. (2016). Promising option for treatment of striae alba: Fractionated microneedle radiofrequency in combination with fractional carbon dioxide laser. *Dermatol Res Pract*. 2896345.
- Fearmonti et al., 2010 – Fearmonti, R., Bond, J., Erdmann, D. et al. (2010). A review of scar scales and scar measuring devices. *Eplasty*. 10: e43.
- Garg, Baveja, 2014 – Garg, S., Baveja, S. (2014). Combination therapy in the management of atrophic acne scars. *J Cutan Aesthet Surg*. 7(1): 18-23.
- Goodman, Baron, 2006 – Goodman, G.J., Baron J.A. (2006). Postacne scarring: a qualitative global scarring grading system. *Dermatol Surg*. 32: 1458-1466.
- Gozali, Zhou, 2015 – Gozali, M.V., Zhou, B. (2015). Effective treatments of atrophic acne scars. *J Clin Aesthet Dermatol*. 8: 33-40.
- Harris et al., 2015 – Harris, A.G., Naidoo, C., Murrell, D.F. (2015). Skin needling as a treatment for acne scarring: An up-to-date review of the literature. *Int J Womens Dermatol*. 1(2): 77-81.

Husain, 2018 – Husain, A. (2018). The efficacy of fractional radiofrequency microneedle system in treatment of facial atrophic acne scars. *International Conference and Expo on Dermatology and Skin Care-Toronto Canada*.

Iyer, Fitzpatrick, 2005 – Iyer, S., Fitzpatrick, R.E. (2005). Long-pulsed dye laser treatment for facial telangiectasias and erythema: evaluation of a single purpuric pass versus multiple subpurpuric passes. *Dermatol Surg.* 31: 898-903.

Kravvas, Al-Niaimi, 2017 – Kravvas, G., Al-Niaimi, F. (2017) A systematic review of treatments for acne scarring. Part 1: Non-energy-based techniques. *Scars Burn Heal.* 3: 2059513117695312.

Maluki, Mohammad, 2012 – Maluki, A.H., Mohammad, F.H. (2012). Treatment of atrophic facial scars of acne vulgaris by Q-Switched Nd:YAG (Neodymium: Yttrium-Aluminum-Garnet) laser 1064nm wavelength. *J Cosmet Laser Ther.* 14: 224-233.

Min et al., 2015 – Min, S., Park, S.Y., Yoon, J.Y., Suh, D.H. (2015). Comparison of fractional microneedling radiofrequency and bipolar radiofrequency on acne and acne scar and investigation of mechanism: comparative randomized controlled clinical trial. *Arch Dermatol Res.* 307: 897-904.

O'Daniel, 2011 – O'Daniel, T.G. (2011). Multimodal management of atrophic acne scarring in the aging face. *Aesthetic Plast Surg.* 35(6): 1143-1150.

Ong, Bashir, 2012 – Ong, M.W., Bashir, S.J. (2012). Fractional laser resurfacing for acne scars: a review. *Br J Dermatol.* 166: 1160-1169.

Saeed et al., 2016 – Saeed, M.Y., Elethawi, A.M.D., Al-Ani, Z.T., Abdullah, R.A. (2016). Application of Fractional Microneedling Radiofrequency and Autologous Platelet-Rich Plasma in Managing Facial Acne Scars. *British Journal of Medicine & Medical Research.* 14(2): 1-18. Article no.BJMMR.24124

Simmons et al., 2014 – Simmons, B.J., Griffith, R.D., Falto-Aizpurua, L.A., Nouri, K. (2014). Use of radiofrequency in cosmetic dermatology: focus on nonablative treatment of acne scars. *Clin Cosmet Invest Dermatol.* 7: 335-339.

Singh, Yadav, 2016 – Singh, A., Yadav, S. (2016). Microneedling: Advances and widening horizons. *Indian Dermatol Online J.* 7(4): 244-254.

Vejjabhinanta et al., 2014 – Vejjabhinanta, V., Wanitphakdeedecha, R., Limtanyakul, P., Manuskiatti, W. (2014). The efficacy in treatment of facial atrophic acne scars in Asians with a fractional radiofrequency microneedle system. *J Eur Acad Dermatol Venereol.* 28(9): 1219-1225.